

Progression of Vision Loss in Macular Telangiectasia Type 2

Tjebo F. C. Heeren,¹ Traci Clemons,² Hendrik P. N. Scholl,³ Alan C. Bird,⁴ Frank G. Holz,¹ and Peter Charbel Issa¹

¹Department of Ophthalmology, University of Bonn, Bonn, Germany

²The EMMES Corporation, Rockville, Maryland, United States

³Wilmer Eye Institute, Johns Hopkins University School of Medicine, Baltimore, Maryland, United States

⁴Moorfields Eye Hospital NHS Foundation Trust and UCL Institute of Ophthalmology, London, United Kingdom

Correspondence: Peter Charbel Issa, Department of Ophthalmology, University of Bonn, Ernst-Abbe-Str. 2, 53127 Bonn, Germany; peter.issa@ukb.uni-bonn.de.

Submitted: March 20, 2015

Accepted: April 20, 2015

Citation: Heeren TFC, Clemons T, Scholl HPN, Bird AC, Holz FG, Charbel Issa P. Progression of vision loss in macular telangiectasia type 2. *Invest Ophthalmol Vis Sci.* 2015;56:3905-3912. DOI:10.1167/iovs.15-16915

PURPOSE. To investigate progressive vision loss in patients with macular telangiectasia (MacTel) type 2 and to compare the ability to detect functional decline between microperimetry and visual acuity testing.

METHODS. Change of cumulative defect size (number of test points with absolute scotoma) on microperimetry testing and change in distance best-corrected visual acuity (BCVA) were evaluated in a prospective longitudinal observational study.

RESULTS. The mean review period was 55.3 months (SD 17.3 months). In 58% of 71 eyes (40 patients) included for analysis, microperimetry revealed spread ($n = 31$) or new development ($n = 10$) of an absolute scotoma. At the same time, BCVA decreased more than two lines in only 17% ($n = 12$). Twenty-five (35%) eyes showed no change in visual function. Presence of an absolute scotoma at baseline, but not baseline BCVA, was predictive for functional decline on longitudinal microperimetry testing. Eyes with an absolute scotoma at baseline ($n = 33$) showed further growth of the scotoma in 94% ($n = 31$). In contrast, only 26% ($n = 10$) of eyes without an absolute scotoma at baseline ($n = 38$) developed an absolute scotoma de novo. Scotoma growth rate (new test points with an absolute scotoma per year) was 0.62 ± 0.10 for all eyes and 1.30 ± 0.12 for the subgroup of eyes with scotoma at baseline. Scotomata always first occurred in the quadrant temporal to the foveal center.

CONCLUSIONS. A characteristic feature in patients with MacTel type 2 is progressive focal loss of macular sensitivity, preceding loss of visual acuity. Microperimetry is sensitive to detect such functional decline and thus may provide considerable power when being used as a functional outcome measure in future clinical trials.

Keywords: macular telangiectasia type 2, microperimetry, functional loss, longitudinal

Macular telangiectasia (MacTel) type 2 is a bilateral macular disease with characteristic vascular changes and localized outer retinal atrophy leading to functional loss within the paracentral and central retina.¹ The prevalence of MacTel type 2 has recently been suggested to be as high as 0.1% in persons 40 years and older,² although the true prevalence might be higher if highly sensitive methods would be used for detecting the disease.¹ Typically, patients notice first symptoms in the sixth and seventh decades of life.³ They may report impaired visual function, including decreased reading ability, metamorphopsia, and reduced visual acuity.^{1,3-5}

Morphological changes include telangiectatic parafoveal capillaries with low-grade leakage on fluorescein angiography, a peculiar retinal graying, crystalline deposits in the superficial retina, and ectatic parafoveal capillaries, often with adjacent blunted venules.¹ Over time, progressive atrophy of the outer neurosensory retina and intraretinal pigmentation may occur. The onset and epicenter of the disease is located temporal to the foveal center at approximately 1 to 2 degrees of eccentricity, but disease manifestations may encompass the entirety of an oval macular area of approximately 1.5 to 2.0 disc diameters centered on the foveola.¹ Neovascular complexes or lamellar and full-thickness macular holes may complicate the disease course in a subset of patients.^{1,6} Characteristic

alterations on optical coherence tomography (OCT) imaging include disruption of the photoreceptor inner segment-outer segment border (ellipsoid zone), hyporeflective cavities at the level of the inner or outer retina, and in later disease stages retinal atrophy mainly confined to the photoreceptor layer.^{1,7} Fundus autofluorescence imaging also may reveal characteristic changes, including a relatively increased signal due to loss of macular pigment resulting in reduced absorption of the excitation light.^{1,8,9}

Although disease progression of MacTel type 2 appears to be slow when assessed with standard methods, some patients report worsening visual function despite stable visual acuity measures. Functional evaluation of patients with MacTel type 2 using fundus-controlled perimetry (microperimetry) revealed characteristic small deep paracentral scotomata that do not necessarily affect performance on single optotype visual acuity testing,¹⁰ but may affect reading and other visual tasks that require an intact paracentral visual field. Indeed, more pronounced reading disability than would be expected from distance visual acuity testing alone correlate with such paracentral focal loss of macular sensitivity.⁵ Moreover, longitudinal data from a recent interventional study showed progressive paracentral visual function loss in a subset of patients while visual acuity remained stable.^{11,12} Vision loss

detected using microperimetry testing also has been found to be associated with a variety of morphological alterations that may develop with disease progression.¹²⁻¹⁶

Despite the functional relevance of the characteristic paracentral sensitivity loss in MacTel type 2, only limited longitudinal observations with relatively few patients and a short follow-up have been reported to date.^{17,18} We hypothesized that progressive functional decline over time mainly occurs in the paracentral visual field and thus can be monitored with higher sensitivity using microperimetry compared with visual acuity testing.

METHODS

In this single-center prospective longitudinal observational study, diagnosis of MacTel type 2 was based on characteristic findings on funduscopy, spectral-domain OCT, and fluorescein angiography (Spectralis HRA-OCT; Heidelberg Engineering, Heidelberg, Germany).¹ Macular pigment distribution (assessed with a modified 2-wavelengths HRA classic; Heidelberg Engineering) showed the typical (para-) central depletion of macular pigment.^{1,8} All patients were recruited at the Department of Ophthalmology, University of Bonn, Germany. Disease staging followed the classification proposed by Gass and Blodi¹⁹ (Supplementary Methods), with stage 0 added for eyes with no obvious disease manifestations, but a fellow eye that allowed the diagnosis. The study was conducted in adherence to the tenets of the Declaration of Helsinki and written informed consent was obtained from every patient. The Department of Ophthalmology, University of Bonn, has approval of the local institutional review board for all study-related data acquisition.

Exclusion criteria were intravitreal injections of VEGF-inhibitors within 3 months and intravitreal application of triamcinolone, photodynamic therapy, or focal argon laser treatment within 12 months before baseline examination. Furthermore, eyes that developed a neovascular complex in the course of the follow-up or a macular hole were excluded from analysis. Inclusion criterion was a minimum follow-up interval of 24 months using high-resolution microperimetry mapping of the macular area (see below).

Functional Testing

Best-corrected visual acuity (BCVA) was measured either by using Snellen charts or by standard Early Treatment Diabetic Retinopathy Study protocols with a transilluminated distance chart.

Fundus-related microperimetry (MP1; Nidek Technologies, Padova, Italy) was performed as described previously.^{10,12} Briefly, the MP1 projects test stimuli (Goldman III size, 100-ms projection time, 4-2 staircase test-strategy) independently from eye movement onto the retina via tracking software, which uses high-contrast anatomical landmarks. We used a 16-degree macula test pattern with a red cross (2 degrees in diameter) as fixation target. The area of expected function loss comprised a central area of 8 degrees horizontally and 4 degrees vertically, centered on the foveola.¹⁰ In this area, the test points were set 1 degree apart from each other.

If an absolute scotoma was present at the border of this central area, additional test points were placed to outline the scotoma. An absolute scotoma was defined as nonperception of the brightest stimulus of the MP1. These and individual test points with questionable validity were retested manually by the examiner. In follow-up examinations, all additional test points were reassessed automatically together with the predefined standard test points.

Data Analysis

For analysis and reporting, visual acuity was converted to logMAR.

Comparison between baseline and follow-up microperimetric examinations revealed that preexisting scotomata could shift within the testing grid, pointing to an inaccuracy of the topographic overlay of follow-up with baseline examinations using the MP1. This assumption was supported by analyzing follow-up examinations using the same microperimeter in patients with other macular diseases that showed a sharp demarcation between abnormal/atrophic and preserved retina (data not shown). Using an automated point-to-point comparison of follow-up examinations with baseline results as integrated in the MP1 software, this inaccuracy may result in a false increase or decrease of sensitivity values (e.g., if the test point at the border of a sharply demarcated scotoma shifts from within the scotoma to an area with preserved retinal sensitivity, or vice versa).

Thus, quantitative analysis of longitudinal microperimetry data included two parameters: the number of test points revealing an absolute scotoma, and the mean sensitivity within the central 4 × 8-degree testing grid.

Statistical Analysis

A *P* value less than 0.05 was considered statistically significant. Because most participants had both eyes included, an analytic method accounting for the correlation between eyes (marginal generalized estimating equations [GEE]) was used.²⁰ In the GEE, dependence within clusters (eyes) is treated as a nuisance parameter and inferences are predicted for population average effects. The least square means, SEs, and 95% confidence intervals (CIs) from generalized linear models are provided. Categorical variables were compared using logistic regression models incorporating the GEE methodology. All analyses were conducted using commercially available statistical software (SAS version 9.2; SAS Institute, Cary, NC, USA).

RESULTS

Seventy-one eyes of 40 patients with MacTel type 2 and a mean age of 64 years (SD 6.1 years; range, 50-74 years) were included in the study. Mean review period was 55.3 months (SD 17.3 months; range, 24-87 months). Baseline characteristics of included and excluded eyes can be found in the Supplementary Results. No eye underwent treatment for MacTel type 2 during the study period, whereas 23 eyes (32%) had a history of previous therapy for this condition (Supplementary Table S1).

Visual Function at Baseline

Descriptive data of visual function at baseline is provided in Table 1. Mean BCVA of all eyes at baseline was logMAR 0.34 (95% CI 0.27-0.40), equivalent to Snellen visual acuity of 20/43. Mean age of patients with and without absolute scotoma in at least one eye (65.4 ± 6.4 years versus 62.3 ± 5.5 years, *P* = 0.10) or with and without BCVA $\leq 20/50$ in at least one eye (64.1 ± 6.9 years versus 63.8 ± 5.3 years, *P* = 0.88) were not statistically different. Presence of an absolute scotoma (*n* = 33; 46% of all eyes) was associated with a significantly worse mean BCVA (*P* < 0.001) and a higher rate of BCVA $\leq 20/50$ (*P* = 0.11) compared with eyes without an absolute scotoma (*n* = 38; 54% of all eyes; Table 1). In eyes with low BCVA ($\leq 20/50$), an absolute scotoma was more frequent (*P* = 0.11) and tended to be larger (*P* = 0.09) than in eyes with better BCVA, yet the difference did not meet statistical significance (Table 1). There was an association between BCVA and microperimetric

TABLE 1. Baseline Characteristics of Visual Function

	<i>n</i>	Mean BCVA, logMAR ± SE		BCVA ≤20/50, <i>n</i> (%)	
All eyes	71	0.34 ± 0.03		25 (35)	
Eyes with absolute scotoma*	33	0.23 ± 0.04	<i>P</i> < 0.001	15 (45)	<i>P</i> = 0.11
Eyes without absolute scotoma	38	0.46 ± 0.04		10 (26)	

	<i>n</i>	Eyes With Absolute Scotoma,* <i>n</i> (%)		No. of Test Points With Absolute Scotoma, Mean ± SE	
All eyes	71	33 (46)		6.8 ± 1.1	
Eyes with BCVA >20/50	46	18 (39)	<i>P</i> = 0.11	4.7 ± 1.1	<i>P</i> = 0.09
Eyes with BCVA ≤20/50	25	15 (60)		8.9 ± 2.1	

* Absolute scotoma of at least one test point.

foveolar light sensitivity (slope -0.0254; *P* < 0.0001) and with light sensitivity at 1 and 2 degrees (slopes -0.0173 and -0.0155; *P* < 0.0001 for both comparisons) temporal to the foveola. Restricting this analysis to eyes with an absolute scotoma, there was an association between BCVA and microperimetric foveolar light sensitivity (slope -0.0164; *P* = 0.04), whereas there was no association between BCVA and light sensitivity at 1 and 2 degrees (slopes 0.0040 and -0.0022; *P* = 0.65 and 0.84, respectively) temporal to the foveola.

At each level within a wide range of BCVA (20/32 to 20/125) approximately half of the eyes revealed presence of an absolute scotoma (Fig. 1A, upper graph), and scotoma size (i.e., the number of test points not seen) was very variable (Fig. 1A, lower graph). However, BCVA >20/32 revealed a lower rate and smaller size of absolute scotomata. A BCVA <20/125 was consistently associated with a larger absolute scotoma.

Absolute scotomata were never observed in disease stages 0 and 1, and only in 1 (6%) of 17 eyes with stage 2 disease. In stage 3, almost half of all eyes (8 of 20; 40%) revealed an absolute scotoma, whereas stages 4 and 5 were always associated with an absolute scotoma (Fig. 1B, upper graph). The size of an absolute scotoma increased with successive disease stages (Fig. 1B, lower graph). If an absolute scotoma was present, loss or pronounced disturbance of the photoreceptor layer was consistently observed on SD-OCT images (data not shown).

Functional Change Over Time

In 41 (58%) of all 71 eyes, microperimetry revealed growth (*n* = 31) or new occurrence (*n* = 10) of an absolute scotoma (Fig. 2A, oblique lines with narrow spacing). Notably, analysis of

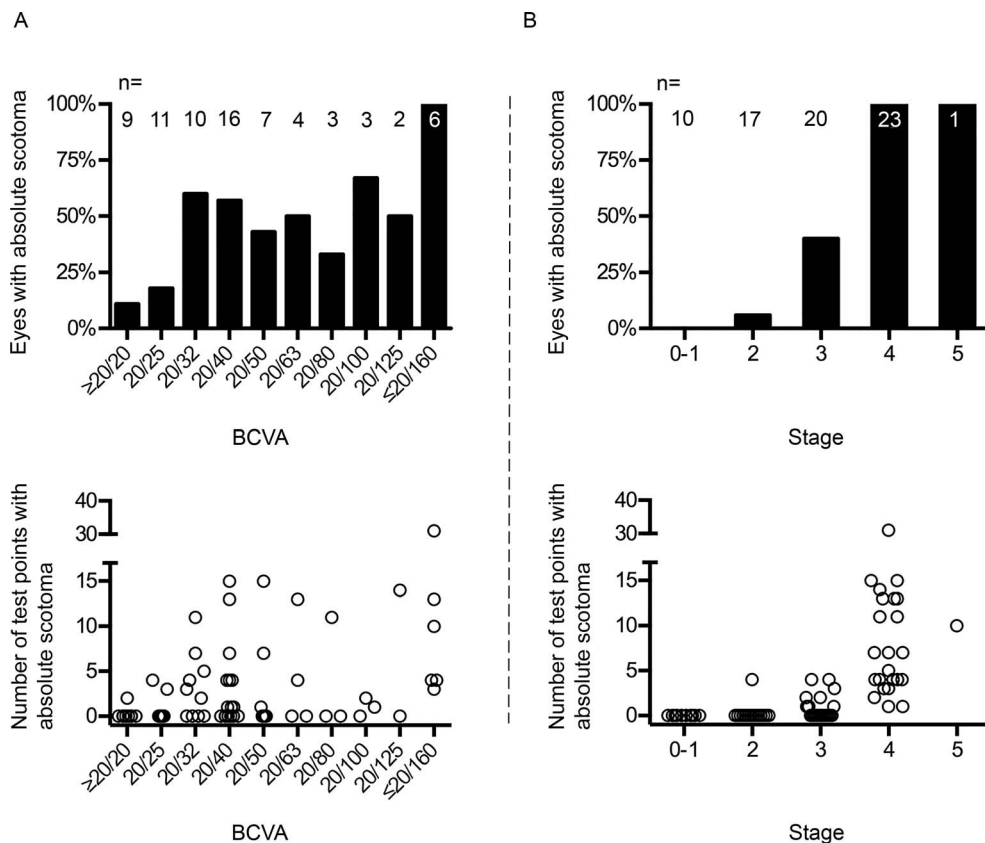


FIGURE 1. Relation between frequency (upper graphs) or size (lower graphs) of absolute scotomata and visual acuity (A) or disease stage (B) at baseline.

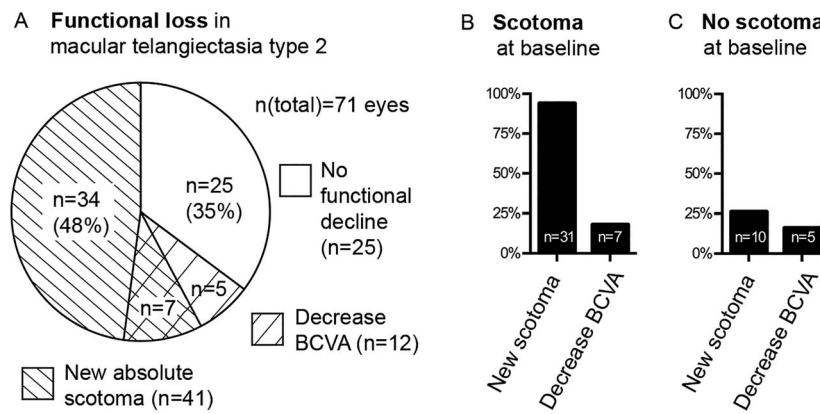


FIGURE 2. Quality of functional loss and its prediction based on microperimetry data. (A) Proportions of functional loss detected by visual acuity and microperimetry testing in patients with macular telangiectasia type 2. (B, C) Proportions of functional loss based on presence or absence of an absolute scotoma at baseline. Presence of a scotoma at baseline significantly predicts further functional loss on microperimetry testing, but has no predictive value for a decrease in visual acuity.

mean sensitivity within the central testing area did not reflect this functional decline (Supplementary Fig. S1). At the same time, BCVA decreased more than two lines in only 12 (17%) of all 71 eyes (Fig. 2A, oblique lines with wide spacing). Functional decline in both parameters (i.e., on visual acuity and microperimetry testing), was noted in 7 (10%) eyes (Fig. 2A, overlapping oblique lines). Thus, detection of visual deterioration was restricted to BCVA and microperimetry testing in 5 (7%) and 34 (48%) eyes, respectively (Fig. 2A). Twenty-five (35%) eyes showed no change in visual function.

Multivariate generalized linear regression revealed presence of an absolute scotoma at baseline, but not baseline BCVA, to be predictive for functional decline on longitudinal microperimetry testing ($P < 0.001$ and $P = 0.76$, respectively). Hence, subgroup analysis was performed with stratification based on presence or absence of a scotoma at baseline (Figs. 2B, 2C). Eyes with an absolute scotoma at baseline showed growth of the scotoma in 94% (31 of 33 eyes; Fig. 2B, left column), whereas only 6% ($n = 2$; right and left eyes of the same patient) remained stable. A total of 10 (26%) of 38 eyes of eyes without an absolute scotoma at baseline developed an absolute scotoma de novo (Fig. 2C, left column).

A significant decrease in BCVA (more than two lines) was not predicted by presence of an absolute scotoma (Figs. 2B, 2C, right columns) or baseline BCVA ($P = 0.70$ and $P = 0.43$, respectively; multivariate generalized linear regression).

Subgroup analysis for functional change on microperimetry and visual acuity testing based on BCVA level at baseline is illustrated in Supplementary Figure S2.

Functional Decline on Microperimetry Testing in Relation to Change in BCVA

In eyes with or without functional decline on microperimetry testing, the frequency of a significant decrease in BCVA (>2 lines; approx. 20%) or stable BCVA (approx. 80%) did not differ statistically ($P = 0.76$; Table 2, upper half). The magnitude of mean BCVA decrease was slightly higher, but did not meet statistical significance, in eyes with scotoma progression (logMAR 0.12 ± 0.04 vs. 0.05 ± 0.02 , $P = 0.14$). When restricting analysis to those eyes that showed a decline in BCVA of more than two lines, the magnitude of BCVA decrease was significantly higher in eyes with compared with those without scotoma progression (logMAR 0.67 ± 0.01 vs. 0.19 ± 0.06 , $P < 0.0001$).

In the subgroup of eyes with development of a new scotoma (i.e., in eyes without a scotoma at baseline), BCVA did not change considerably in nine of ten eyes (mean logMAR 0.15 to 0.2). Only in one of the ten eyes of this subgroup, BCVA dropped from logMAR 0.3 to 1.0 due to incident subfoveal atrophy.

The approximate 60% frequency of functional decline on microperimetry testing as described above was independent from change in BCVA of more than two lines ($P = 0.73$; Table 2, lower half).

Proximity of an absolute scotoma to the foveal center was associated with lower BCVA (Fig. 3, slope -0.1394 ; $P = 0.04$). There were three eyes with pronounced drop of BCVA, which occurred due to enlargement of the absolute scotoma into the foveal center. Examples of the natural history of scotoma

TABLE 2. Functional Changes on Microperimetry in Relation to Change in Visual Acuity

	<i>n</i>	Decrease in BCVA >2 Lines, <i>n</i> (%)	BCVA Stable, <i>n</i> (%)
Functional decline on microperimetry*	41	8 (20)	33 (80)
No change on microperimetry	30	5 (17)	25 (83)
	<i>n</i>	Functional Decline on Microperimetry, <i>n</i> (%)	No Change on Microperimetry, <i>n</i> (%)
Decrease in BCVA >2 lines	13	8 (62)	5 (38)
BCVA stable	48	33 (57)	25 (43)

* Increasing number of testing points with an absolute scotoma.

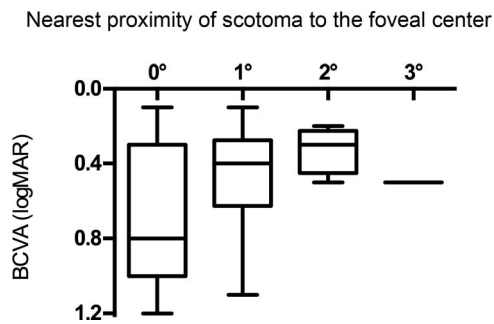


FIGURE 3. Association of proximity of absolute scotomata to the foveal center with BCVA.

progression are shown in Figure 4 and Supplementary Figure S3. Change of retinal function on microperimetry and BCVA testing for each individual eye is summarized in Supplementary Figure S4.

Topographic Characteristics of Functional Loss

The locus and progression of functional loss determined by microperimetry followed a common pattern. If a scotoma was present, it was consistently monofocal and affected the temporal quadrant, most frequently at approximately 2 degrees temporal/temporal-inferior from the foveal center (Fig. 5A). Independent from spread of a scotoma over time, this epicenter of functional loss remained throughout the review period. Other quadrants revealed areas of functional loss when a scotoma enlarged from the temporal area. Most commonly, such enlargement was observed into the inferior quadrant, followed by the superior and nasal quadrants (Fig. 5B). At the last follow-up, scotomata

were localized in the temporal and the inferior quadrants in 100% and 70%, respectively (Fig. 5C). In absolute terms, 50% and 20%, respectively, of all test points with an absolute scotoma were located in those two quadrants (Fig. 5D).

Enlargement of an absolute scotoma occurred at the edge of preexisting absolute scotomata. Only in two eyes of one patient (5%), a new test point with absolute scotoma emerged separately, but in proximity to the preexisting scotoma.

Scotoma Growth Rate

In Figure 6, individual rates of function loss on microperimetry testing are plotted against age. Similar to other retinal degenerative diseases,^{21,22} a model may be applied to better understand the functional decline on microperimetry testing in patients with MacTel type 2. The model consists of two parameters: a time delay or age at scotoma onset, and the progression rate observed thereafter. Despite the variable scotoma size (y -axis) observed in this study, there appears to be little variability of individual slopes as measure for progression rates (Fig. 6A). Thus, the age of onset of a scotoma may be the dominant contributor to the observed variability in functional loss. The age of onset of a scotoma is the intercept of the x -axis with the progression line and may be calculated for each eye by fitting a progression line through individual sensitivity losses using the equation $Y = 1.3^x \text{year}$ (see below). Replotting the data against time after age of scotoma onset demonstrates the common natural history of scotomata in patients with MacTel type 2 (Fig. 6B).

On microperimetric testing, the mean (\pm SE) functional decline of all 71 eyes was 0.62 (\pm 0.10) (95% CI 0.42-0.83) new test points with an absolute scotoma per year. The subgroup of eyes with an absolute scotoma at baseline had a

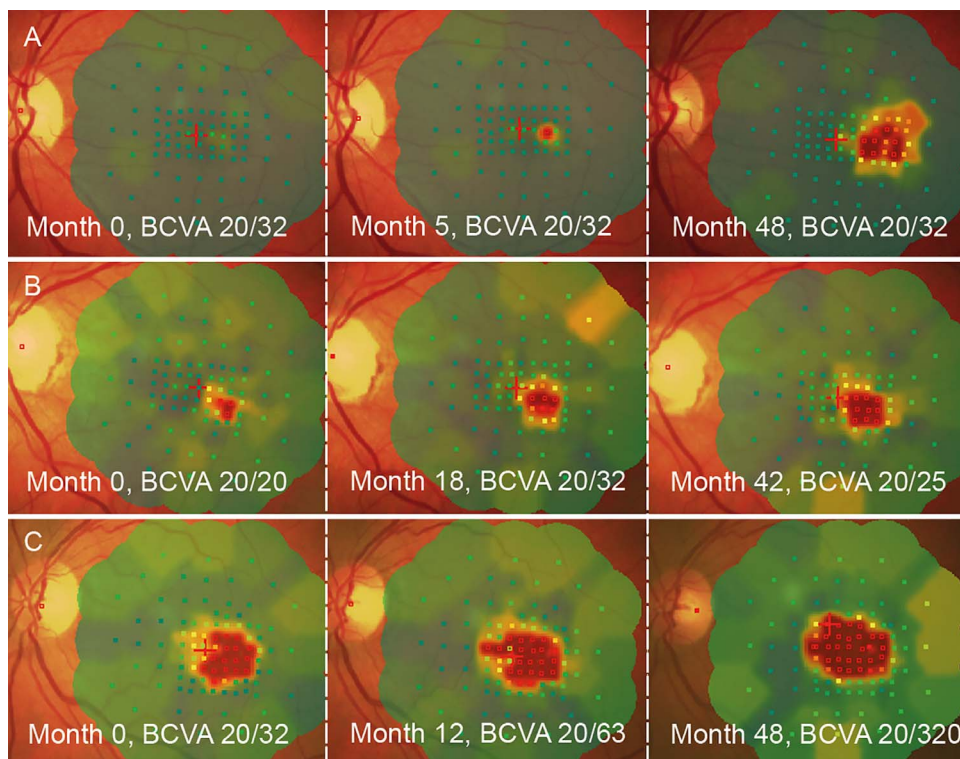


FIGURE 4. Representative longitudinal follow-up microperimetry examinations in three eyes of three patients. (A) Example of development of a new scotoma. A neovascular complex was present 48 months after baseline, resulting in exclusion from our analysis. (B) Example of growth of a preexisting scotoma. (A, B) In both eyes, BCVA remained stable during the follow-up period. (C) Example for growth of a scotoma into the foveal center, leading to pronounced decrease in BCVA. Note the eccentric shift of the fixation cross.

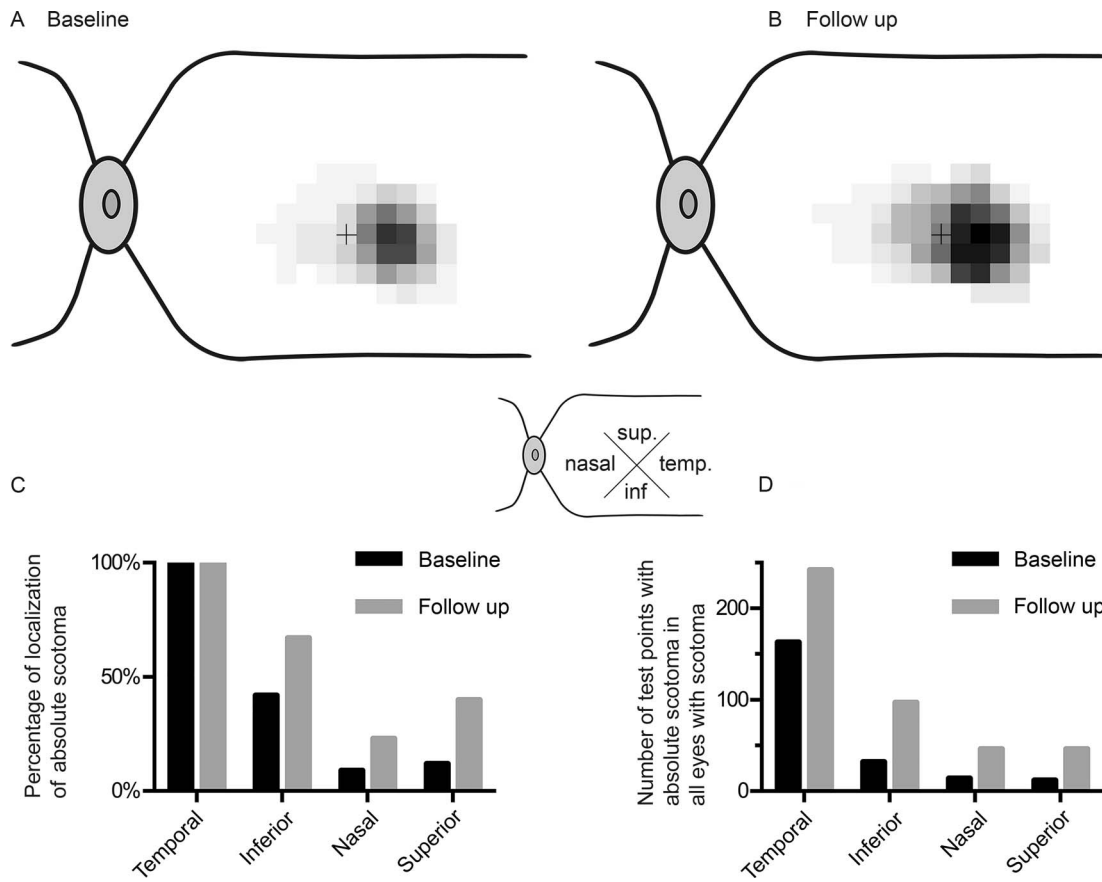


FIGURE 5. Topographic distribution of scotomata at baseline and last follow-up. *Upper graphs (A, B):* Gray level represents the cumulative frequency of an absolute scotoma at a given test location. *Darker gray level* means more frequent vision loss. Each *square* represents individual testing points, enlarged for better visualization. The *lower graphs* show the frequency of presence of an absolute scotoma in the different quadrants (C) and the size of the absolute scotoma (D) in the respective quadrants in eyes with absolute scotomata.

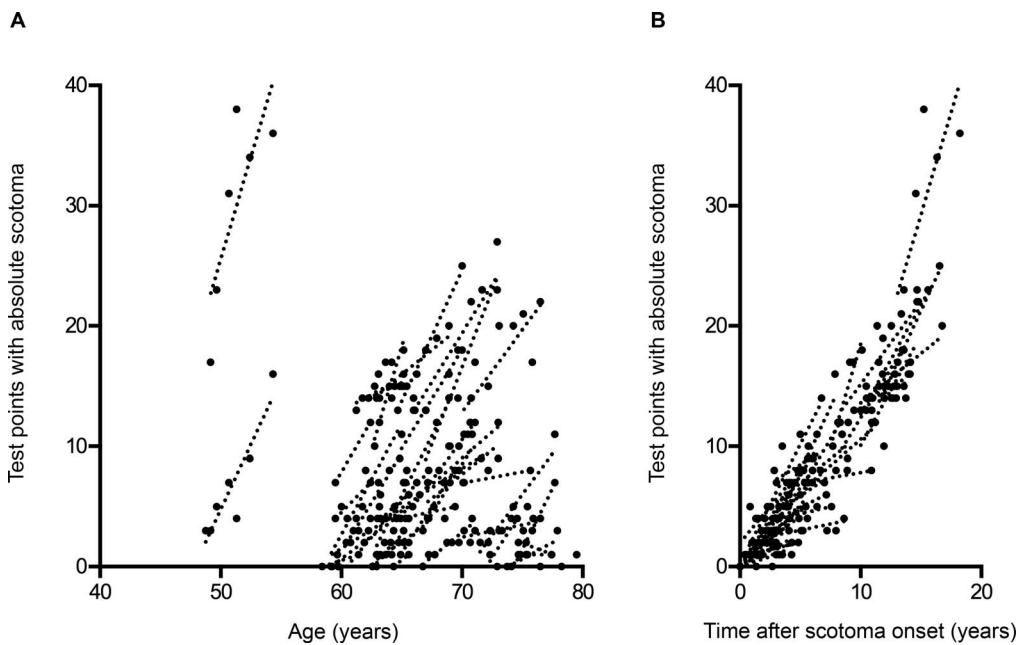


FIGURE 6. Rate of functional decline on microperimetry testing. Trend lines are plotted for serial evaluations of individual eyes. (A) Scotoma growth rate is relatively uniform across eyes. (B) Growth rate after age of scotoma onset supports the common disease progression with little influence of the delay before development of an absolute scotoma.

mean (\pm SE) growth rate of 1.30 (\pm 0.12) (95% CI 1.07–1.53) new test points with an absolute scotoma per year. In this cohort, the scotoma enlargement rate was independent from the size of a preexisting scotoma ($P = 0.57$) and baseline visual acuity ($P = 0.59$).

Mean age of patients with and without progression on microperimetry testing was 64.1 ± 5.6 and 64.1 ± 6.4 years at baseline, respectively ($P = 0.99$). Given the small number of young participants, there is obviously a limitation with regard to power to find a potential association of growth rate with age at scotoma onset.

DISCUSSION

For MacTel type 2, a first clinical trial using a neuroprotective approach is under way,²³ aiming at slowing or stopping the characteristic photoreceptor degeneration of the central retina. However, natural history studies that allow conclusions on meaningful functional outcome measures are scarce. Ideally, an outcome measure used in a clinical trial is meaningful for the patient, reliably indicates disease progression, and shows considerable change within a study time frame.

The most commonly used endpoint of therapeutic studies for retinal disease has been single optotype BCVA, a parameter that largely depends on central foveal function. In MacTel type 2, however, functional decline typically initially spares the foveal center. Thus, other clinical parameters may be needed to monitor paracentral loss of function so as to evaluate disease progression and/or therapeutic effects. The current study took a step toward defining disease progression in MacTel type 2 as measured by microperimetry, a method that allows mapping retinal function over a wider macular area.²⁴

Microperimetry Versus BCVA Testing for Monitoring Vision Loss in MacTel Type 2

Within the entire cohort, functional deterioration was more frequently observed on microperimetry compared with BCVA testing (58% vs. 17%). This suggests that change in sensitivity within the (para-) central visual field is more sensitive than change in BCVA for detecting functional decline in patients with MacTel type 2. This conclusion is in line with a recent observation in a small prospective clinical trial in which BCVA remained stable while there was a functional decline on microperimetry testing.^{11,12}

In the subgroup of patients with a preexisting absolute scotoma at baseline, almost all eyes (94%) revealed further vision loss on microperimetry testing during the observational period, whereas only 18% of the same group revealed a significant deterioration of BCVA. This natural history observation suggests that patients with an absolute scotoma would be good candidates for clinical trials because there would typically be measurable disease progression during a relatively short period of time.

Reading as one of the most important visual abilities has recently been reported to be considerably affected by paracentral scotomata in patients with MacTel type 2.⁵ Moreover, assessment of the vision-targeted health-related quality of life revealed lower vision-related functioning compared with a reference group with macular degeneration that had the same level of central visual acuity.²⁵ It was concluded that functional outcome measures different from distance visual acuity testing appear to be necessary to fully evaluate the functional deficits in MacTel type 2. Thus, vision loss detected by microperimetry, although not necessarily correlated with BCVA, may be meaningful for the patients' quality of life.

The baseline characteristics of the reported cohort show that BCVA may drop before occurrence of an absolute scotoma.

However, it should be noted that significant deterioration of BCVA may be very slow and that it occurs only in a subset of patients before the onset of a paracentral scotoma. There is currently no biomarker that allows determining which patient will develop deteriorating BCVA before or after the incidence of an absolute scotoma.

Topography of Function Loss

The consistent onset of an absolute scotoma in the temporal/temporal-inferior region and the predominant localization within this area in later disease stages confirm the previously suggested epicenter of the disease.^{1,10,26} Enlargement of a scotoma regularly occurred at the border of a preexisting scotoma, suggesting that the underlying photoreceptor loss spreads from the disease epicenter.

Scotomata rarely enlarged beyond the central testing grid covering the central retinal area (8 degrees horizontally, 4 degrees vertically), and no relevant change was detected outside this area (Supplementary Fig. S1). Therefore, restriction of microperimetry testing to this central region of expected function loss appears sufficient for future longitudinal observations in MacTel type 2, limiting the duration of this time-consuming psychophysical assessment. In selected cases, mostly in much progressed disease stages, additional testing points may be necessary for complete scotoma mapping.

Scotoma Onset and Growth Rate

To detect localized enlargement or development of a scotoma in a cohort with heterogeneous baseline characteristics, a relatively large and dense test grid is necessary. In this study, 45 test points covering the central 4×8 degrees were used. Consequently, there is little impact of one or few test points with new absolute scotomata on change of mean sensitivity across the tested area (Supplementary Fig. S1). Such local visual field defects are therefore characterized better by quantification of the cumulative defect size, in this case the number of testing points with a defined loss of function.

Once an absolute scotoma had developed, it enlarged within the study period in 94%. The age of scotoma onset may mark a time point at which localized incident photoreceptor death can first be detected using microperimetry as surrogate measure. After such initial event, a relatively uniform progression of photoreceptor death is suggested to be the natural disease course, which might eventually involve the entire oval macular area typically affected by MacTel type 2. The time delay to reach the age of scotoma onset may add variability, suggesting an influence of environmental and/or genetic modifying factors. However, such conclusion currently remains presumptive because the current study was not designed to test such hypothesis.

Conclusions on the kinetics of photoreceptor death in MacTel type 2 (i.e., if it follows a cumulative damage model or a one-hit model),²⁷ cannot be derived from this limited dataset with a relatively short observation period. It is likely that there is a slowdown of photoreceptor degeneration and death with time because of the limited area affected by the disease process in MacTel type 2. The dataset also was too small to detect a potential interaction with age. For instance, there might be a faster progression of functional decline in those who develop a scotoma at a younger age.

Almost no eyes in stage 2 and all eyes in stage 4 present with an absolute scotoma. Accordingly, first occurrence of an absolute scotoma would occur in stage 3 of the Gass and Blodi classification. Indeed, almost 50% of all stage 3 eyes presented with an absolute scotoma. Future studies may evaluate if stage 3 predicts development of an absolute scotoma, or if stage 3 should rather be divided into different stages based on

functionally relevant specific morphological alterations that are not considered in the current staging system.

CONCLUSIONS

MacTel type 2 leads to progressive paracentral vision loss, which may precede significant loss of visual acuity, affect the patient's visual ability, and, thus, quality of life. Microperimetry for mapping the characteristic paracentral scotomata may be more sensitive to detect and monitor functional decline than BCVA testing. In patients with presence of a scotoma, microperimetry reliably detects disease progression within a time frame relevant for clinical trials. Therefore, functional testing using microperimetry may be superior to visual acuity testing as a functional outcome measure in clinical trials.

Acknowledgments

Supported by ProRetina and Lowy Medical Research Institute. HPNS is the Dr. Frieda Derdeyn Bambas Professor of Ophthalmology. The sponsor or funding organization had no role in the design and conduct of the study; collection, management, analysis, and interpretation of the data; and preparation, review, or approval of the manuscript.

Disclosure: **T.F.C. Heeren**, None; **T. Clemons**, The EMMES Corporation (E); **H.P.N. Scholl**, Fovea Pharmaceuticals (C), Trevena Inc. (C), Guidepoint Global, LLC (C), Gerson Lehrman Group (C), StemCells, Inc. (C), Genzyme Corp. (C), QLT, Inc. (F); **A.C. Bird**, None; **F.G. Holz**, Alcon (C), Acucela (C), Genentech (C), Roche (C), Bayer (C), Novartis (C), Merz (C); **P. Charbel Issa**, Novartis (R), Bayer (R)

References

- Charbel Issa P, Gillies MC, Chew EY, et al. Macular telangiectasia type 2. *Prog Retin Eye Res.* 2013;34:49–77.
- Klein R, Blodi BA, Meuer SM, Myers CE, Chew EY, Klein BEK. The prevalence of macular telangiectasia type 2 in the Beaver Dam Eye Study. *Am J Ophthalmol.* 2010;150:55–62.
- Heeren TF, Holz FG, Charbel Issa P. First symptoms and their age of onset in macular telangiectasia type 2. *Retina.* 2013;34:916–919.
- Charbel Issa P, Holz FG, Scholl HPN. Metamorphopsia in patients with macular telangiectasia type 2. *Doc Ophthalmol.* 2009;119:133–140.
- Finger RP, Charbel Issa P, Fimmers R, Holz FG, Rubin GS, Scholl HPN. Reading performance is reduced due to parafoveal scotomas in patients with macular telangiectasia type 2. *Invest Ophthalmol Vis Sci.* 2009;50:1366–1370.
- Charbel Issa P, Scholl HP, Gaudric A, et al. Macular full-thickness and lamellar holes in association with type 2 idiopathic macular telangiectasia. *Eye.* 2009;23:435–441.
- Gaudric A, Ducos de LG, Cohen SY, Massin P, Haouchine B. Optical coherence tomography in group 2A idiopathic juxtafoveal retinal telangiectasis. *Arch Ophthalmol.* 2006;124:1410–1419.
- Charbel Issa P, van der Veen RLP, Stijfs A, Holz FG, Scholl HPN, Berendschot TTJM. Quantification of reduced macular pigment optical density in the central retina in macular telangiectasia type 2. *Exp Eye Res.* 2009;89:25–31.
- Helb HM, Charbel Issa P, van der Veen RLP, Berendschot TTJM, Scholl HPN, Holz FG. Macular pigment density and distribution in patients with type II macular telangiectasia. *Retina.* 2008;28:808–816.
- Charbel Issa P, Helb HM, Rohrschneider K, Holz FG, Scholl HP. Microperimetric assessment of patients with type 2 idiopathic macular telangiectasia. *Invest Ophthalmol Vis Sci.* 2007;48:3788–3795.
- Charbel Issa P, Finger RP, Kruse K, Baumüller S, Scholl HP, Holz FG. Monthly ranibizumab for nonproliferative macular telangiectasia type 2: a 12-month prospective study. *Am J Ophthalmol.* 2011;151:876–886.
- Charbel Issa P, Tröger E, Finger R, Holz FG, Wilke R, Scholl HPN. Structure-function correlation of the human central retina. *PLoS One.* 2010;5:e12864.
- Sallo FB, Peto T, Egan C, et al. “En face” OCT imaging of the IS/OS junction line in type 2 idiopathic macular telangiectasia. *Invest Ophthalmol Vis Sci.* 2012;53:6145–6152.
- Zeimer MB, Padge B, Heimes B, Pauleikhoff D. Idiopathic macular telangiectasia type 2: distribution of macular pigment and functional investigations. *Retina.* 2010;30:586–595.
- Maruko I, Iida T, Sekiryu T, Fujiwara T. Early morphological changes and functional abnormalities in group 2A idiopathic juxtafoveal retinal telangiectasis using spectral domain optical coherence tomography and microperimetry. *Br J Ophthalmol.* 2008;92:1488–1491.
- Wong WT, Forooghian F, Majumdar Z, Bonner RF, Cunningham D, Chew EY. Fundus autofluorescence in type 2 idiopathic macular telangiectasia: correlation with optical coherence tomography and microperimetry. *Am J Ophthalmol.* 2009;148:573–583.
- Schmitz-Valckenberg S, Ong EEL, Rubin GS, et al. Structural and functional changes over time in MacTel patients. *Retina.* 2009;29:1314–1320.
- Sallo FB, Peto T, Egan C, et al. The IS/OS junction layer in the natural history of type 2 idiopathic macular telangiectasia. *Invest Ophthalmol Vis Sci.* 2012;53:7889–7895.
- Gass JD, Blodi BA. Idiopathic juxtafoveal retinal telangiectasis. Update of classification and follow-up study. *Ophthalmology.* 1993;100:1536–1546.
- Liang K-Y, Zeger SL. Longitudinal data analysis using generalized linear models. *Biometrika.* 1986;73:13–22.
- Cideciyan AV, Swider M, Aleman TS, et al. ABCA4 disease progression and a proposed strategy for gene therapy. *Hum Mol Genet.* 2009;18:931–941.
- Iannaccone A, Kritchevsky SB, Ciccarelli ML, et al. Kinetics of visual field loss in Usher syndrome Type II. *Invest Ophthalmol Vis Sci.* 2004;45:784–792.
- Chew EY, Clemons TE, Peto T, et al. Ciliary neurotrophic factor for macular telangiectasia type 2: results from a phase 1 safety trial. *Am J Ophthalmol.* 2015;159:659–666.e1.
- Rohrschneider K, Bultmann S, Springer C. Use of fundus perimetry (microperimetry) to quantify macular sensitivity. *Prog Retin Eye Res.* 2008;27:536–548.
- Clemons TE, Gillies MC, Chew EY, et al. The National Eye Institute Visual Function Questionnaire in the Macular Telangiectasia (MacTel) Project. *Invest Ophthalmol Vis Sci.* 2008;49:4340–4346.
- Barthelmes D, Gillies MC, Sutter FK. Quantitative OCT analysis of idiopathic perifoveal telangiectasia. *Invest Ophthalmol Vis Sci.* 2008;49:2156–2162.
- Clarke G, Lumsden CJ, McInnes RR. Inherited neurodegenerative diseases: the one-hit model of neurodegeneration. *Hum Mol Genet.* 2001;10:2269–2275.